


PRESENTING CLINICAL SIGNS
DATE History: Grade 4/6 murmur.

3/17/23 **ECHOCARDIOGRAPHIC FINDINGS**
 2D, M-mode, and Doppler study.

PERFORMED BY: There is mild left atrial dilation. The mitral valve is normal. Left ventricular wall thickness is normal. Left ventricular internal dimensions are normal. Left ventricular systolic function is hyperdynamic. The aorta and aortic valve appear normal, though there is very mildly increased flow velocity in the ascending aorta. Right atrial and right ventricular dimensions are normal. The tricuspid valve appears normal, though trace tricuspid regurgitation is present. The pulmonary artery and pulmonic valve are normal. No shunting lesions are visualized. No heartworms are visualized. No pericardial effusion or cardiac masses are seen.

Kelly Vazquez

INTERPRETED BY

 Keith Blass, DVM,
 MS, DACVIM
 (Cardiology)

 LA/Ao - 1.56
 IVSd - 4.4 mm
 LVPWd - 4.4 mm
 LVIDd - 16.9 mm
 LVIDs - 7.3 mm
 FS - 56.8%
 LVOT - 1.52 m/s
 RVOT - 1.32 m/s

PATIENT

Willy Bertotti

SPECIES **ASSESSMENT/RECOMMENDATIONS**

Feline This examination demonstrates mild dilation of Willy's left atrium, with differentials for this finding including a restrictive cardiomyopathy (RCM), atrial myopathy, and cardiac thyrotoxicosis. As only mild chamber dilation is present, Willy's current risk for the development of congestive heart failure, thromboembolic disease, and/or arrhythmia formation appears to be relatively low, though careful monitoring for clinical signs associated with these conditions is recommended.

BREED
DSH

Willy's murmur appears to be due to the presence of very mildly increased flow velocity in his aorta, which is a common reason for a functional/innocent murmur to develop in cats.

SEX

A T4 level is recommended.

MN

I recommend starting Willy on clopidogrel (18.75 mg SID), as this medication should help to reduce his risk for cardiac thrombus formation.

AGE

14 y

A recheck echocardiogram is recommended in 6 months. Thoracic radiographs are recommended if Willy experiences respiratory clinical signs.

WEIGHT

13.24 lb

HOSPITAL NAME

 Westwood Regional
 VH

REFERRING VET

Dr. Hartwick



DATE

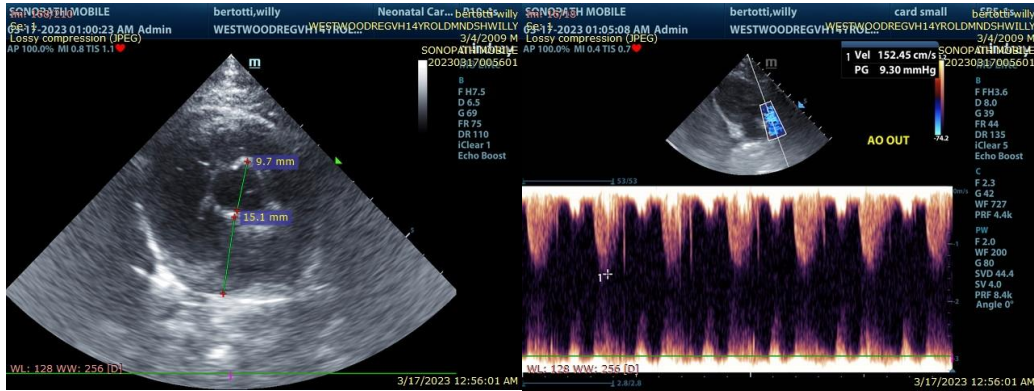
3/17/23

PERFORMED BY:

Kelly Vazquez

INTERPRETED BY

Keith Blass, DVM,
MS, DACVIM
(Cardiology)



The information and recommendations provided are based on the images presented by the referring veterinarian. No evaluation can be communicated regarding pathology that was not visible in the image/video clips provided.

PATIENT

Willy Bertotti

Thank you for this referral. If the clinical or image interpretation does not parallel your findings or if I can be of any further assistance please contact me.

Keith Blass, DVM, MS, DACVIM (Cardiology)
KeithBlass@gmail.com

SPECIES

631-804-5754

Feline

BREED

DSH

SEX

MN

AGE

14 y

WEIGHT

13.24 lb

HOSPITAL NAME

Westwood Regional
VH

REFERRING VET

Dr. Hartwick